

## **ANATOMY, BIOMECHANICS, PHYSIOLOGY, DIAGNOSIS AND TREATMENT OF TERES MAJOR STRAINS IN THE CANINE**

**Laurie Edge-Hughes, BScPT, CAFCI, CCRT**

Four Leg Rehabilitation Therapy & The Canine Fitness Centre Ltd, Calgary, AB, Canada

The Canadian Horse and Animal Physical Rehabilitation Assn.

The Animal Rehab Institute, Loxahatchee, Florida, USA

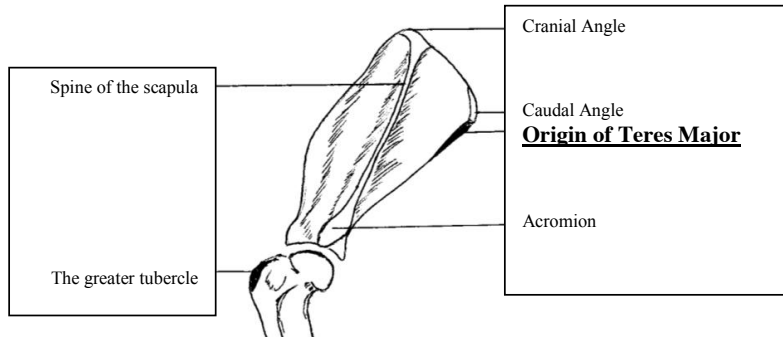
### **BACKGROUND**

The canine shoulder apparatus is unique as compared to other canine joints and also when compared to the human shoulder. When compared to the hind limb it is interesting to note that the front limb has no bony attachment to the axial skeleton in that there is no clavicle in the canine. This factor alone means that muscular strength and co-ordination is of utmost importance to full functioning of the front limb. When compared to the human shoulder, one obvious difference is that the shoulder joint is a weight bearing joint. The orientation of the canine scapula and humerus is vertical and the weight distribution is 60 to 65 % on the front legs and 40 – 35% on the hind legs. Essentially dogs are like ‘front wheel drive vehicles’, designed to propel themselves forward by primarily ‘pulling’ from the front end. This is why identification and treatment of front limb muscle injuries is critically important for athletic or just high energy dogs who are most prone to injuring shoulder muscles. The teres major muscle is one that is commonly strained, often unidentified and hence not as effectively treated as it could be in the active canine patient.

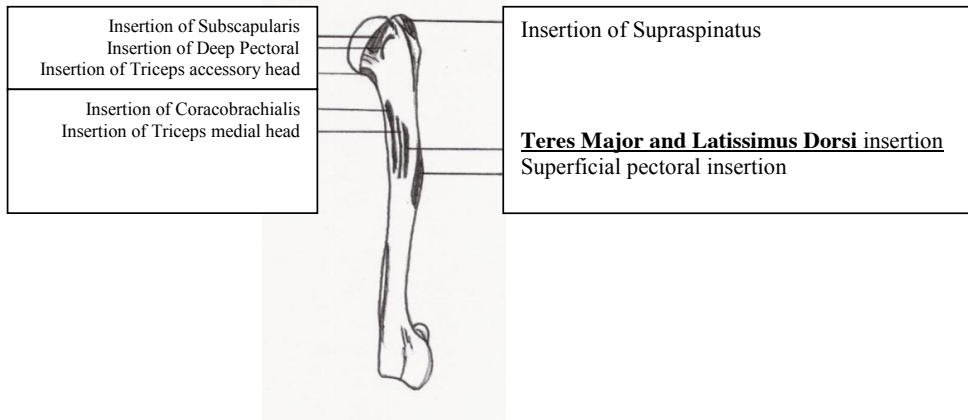
### **ANATOMY**

The teres major muscle originates from the caudal angle and caudal edge of the scapula and inserts into the eminence on the proximal 1/3 of the medial surface of the humerus. It shares a common tendon of insertion with the latissimus dorsi. In humans, the Teres Major muscles has an action to adduct, medially rotate and draw the arm back. In analyzing the origins and insertion of Teres Major in the canine, this muscles action must also be to flex the shoulder as well as to adduct and internally rotate the shoulder when the front limb is in an outstretched position. Given that it shares a common tendon with the latissimus dorsi, one might also assume that it is an important muscle involved in forward propulsion, drawing the trunk forward when the front leg is fixed, just as Latissimus dorsi does. As well, tensor fascia antebrachii (an elbow extensor) utilizes the fascia on the lateral side of the latissimus dorsi as its origin which can mean that a malfunctioning teres major and latissimus dorsi complex may also have an affect on elbow extension. A true assessment of teres major functioning would require EMG studies but this paper will serve only as a clinical study and application.

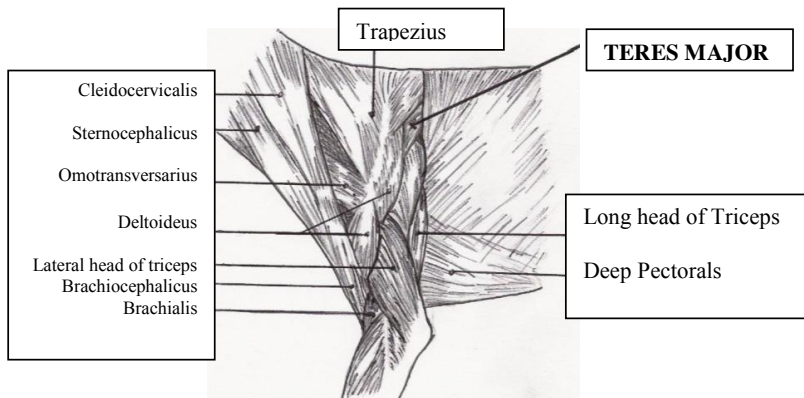
Edge-Hughes, LM Anatomy, biomechanics, physiology, diagnosis and treatment of teres major strains in the canine. Proceedings of the RVC 2nd Annual Veterinary Physiotherapy Conference, Suppl. 2004.



Boney Landmarks for the shoulder (lateral aspect)

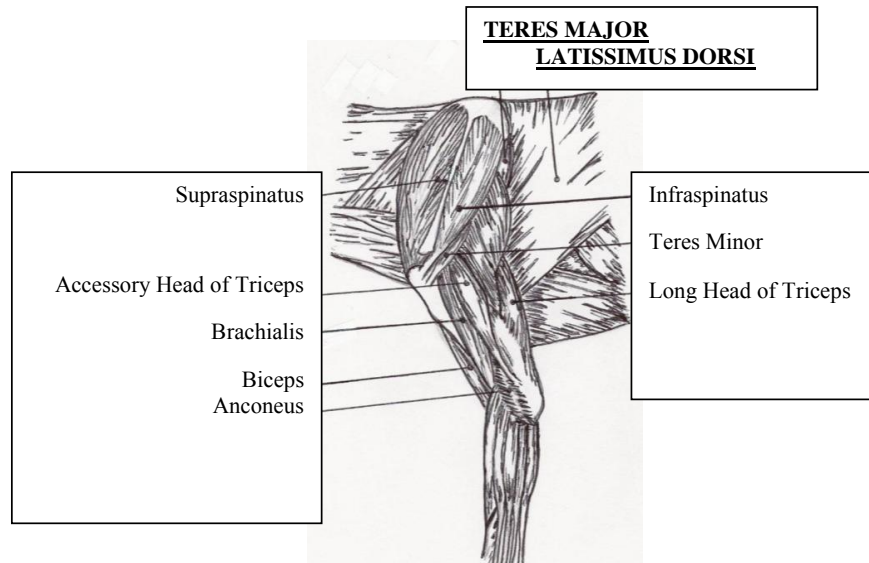


Muscular Attachment to the humerus, medial aspect

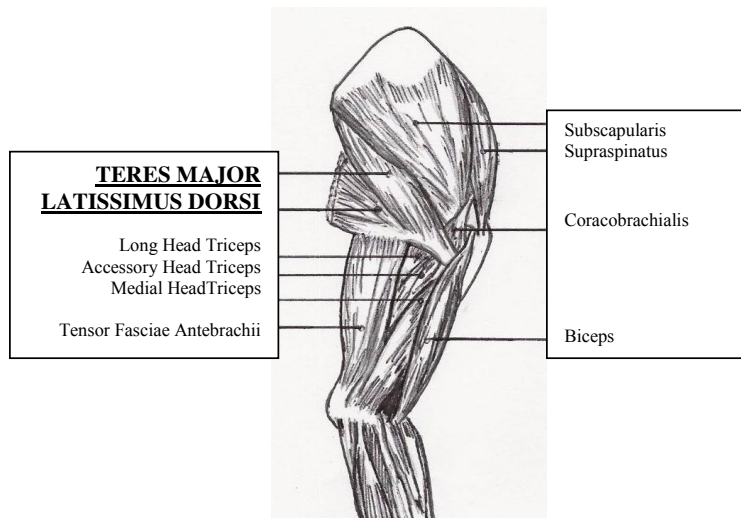


Superficial muscles of the forelimb, lateral aspect

Edge-Hughes, LM Anatomy, biomechanics, physiology, diagnosis and treatment of teres major strains in the canine. Proceedings of the RVC 2nd Annual Veterinary Physiotherapy Conference, Suppl. 2004.



Deep Muscles of the Forelimb, lateral aspect



Muscles of the forelimb, medial aspect

Edge-Hughes, LM Anatomy, biomechanics, physiology, diagnosis and treatment of teres major strains in the canine. Proceedings of the RVC 2nd Annual Veterinary Physiotherapy Conference, Suppl. 2004.

## BIOMECHANICS

According to Millers Anatomy, the Teres Major muscle acts to flex the shoulder joint. However if we look to origin and insertion, we can ascertain more about this muscle. In fact, the Teres Major must assist to return the forelimb to neutral from an outstretched position or to move the body toward an outstretched front limb, as when a dog is turning. Essentially, its full action is flexion, adduction and internal rotation of the shoulder joint. Therefore, the mechanics involved in its getting strained would be an exaggerated extension, abduction and external rotation. This action can occur when a dog is running at high speeds, plants it's foot and turns in the opposite direction as when it is running after a ball, makes a grab for it and simultaneously turns to return to the ball thrower or when turning quickly and sharply as in canine agility sports. Such overextension of the limb can occur when the ground is slippery with ice or snow or with near 180 degree agility course changes of direction. In fact it can be so common in the agility dogs that this injury could be given the nickname 'agility pit'...much like lateral epicondylitis sports the name 'tennis elbow'!

## PHYSIOLOGY

To gain an appreciation of what happens to the muscle and/or tendon during a strain it is important to understand the physiology of the strain. This will assist not only with diagnostics, but later, when we apply treatment protocols and rationale. When muscles or tendons are strained, micro or macro tearing has occurred to the muscle or tendon tissues. When soft tissue is strained there is a predictable pattern of damage. Grade one strains involve myositis, and contusion. Grade two strains can have both myositis as well as tearing of the sheath and/or disruption of muscle fibres with haematoma formation. Grade three strains (according to human classification systems) are actually complete ruptures of the muscle or tendon. There are no fibres left intact, and non-surgical healing of that musculo-tendinous unit is not possible. The nerve fibres within the structure are also ruptured so these animals may exhibit less pain than those with partial tears. Clinically you see the following:

### 1<sup>st</sup> Degree Strains:

- Localized pain on palpation
- Mild muscle spasm
- Mild or absent heat
- Minor disability or loss of function
- +/- lameness
- Mild swelling
- Discomfort, mild or moderate pain to stretch the structure

### 2<sup>nd</sup> Degree Strains:

- Localized moderate to extreme pain on palpation
- Moderate to severe muscle spasm
- Heat detected on palpation
- Moderate disability or loss of function
- Variable lameness
- Swelling
- Moderate to severe pain to stretch the structure

Edge-Hughes, LM Anatomy, biomechanics, physiology, diagnosis and treatment of teres major strains in the canine. Proceedings of the RVC 2nd Annual Veterinary Physiotherapy Conference, Suppl. 2004.

### 3<sup>rd</sup> Degree Strains (Ruptures)

- Marked lameness
- Severe disability / loss of function
- Subcutaneous hemorrhage
- Marked swelling and haematoma
- Pain to palpate proximal portion of muscle or tendon
- Palpable disruption of tissues / Asymmetry of limbs
- Possibly no pain to stretch the affected tissue

An understanding of the repair process of muscle and tendon injuries also assists us with diagnosis and later treatment of these problems. Tissue repair also happens in a predictable fashion. After an injury to connective tissue (ligament, tendon or muscle), it goes through the following phases in order to heal.

- EARLY Stage 1: Hemorrhagic Phase (24 – 48hours). In this phase there are cellular changes, swelling, and granulation tissue begins to form which needs oxygen and nutrients, so capillaries can divide and grow.
- END Stage 1: Substrate Phase (Days 3 – 5): In this stage the dead cells and damaged collagen from the injury are removed or broken down.
- STAGE 2: The Regeneration Phase (Days 5 – 21, but can last for up to 15 weeks depending upon the severity of the injury or the body's ability or opportunity to heal.) In this stage there is the formation of new muscle fibres by myoblasts and collagen fibres by fibroblasts. The fibroblasts lay down new small weak fibres in a disorganized fashion resulting in the formation of fibrous scar tissue usually by day 10. The myofibrils continue to divide and infiltrate into this collagen network. Their ability to do so will affect the chances of that portion of the muscle to actively contract again. The tensile strength of the muscle or tendon has the chance to increase during this time so long as appropriate stimulus is applied. Collagen synthesis is at its greatest at the two week post-injury period.
- STAGE 3: The Remodeling phase (can take up to a year following the regeneration phase). This involves the strengthening and thickening of the collagen fibres and continued re-orientation. During this phase vascularity may have decreased and scar tissue built up.
- Chronic musculotendinous (or ligamentous) injuries will have random collagen orientation, wound contracture and restrictive adhesions. In these cases the injury was not properly addressed and the primary healing process has already occurred. The injury site healed in a weak disorganized fashion and continues to receive micro strains whenever it is overly stressed. Since scar tissue tends to contract or retract, tissue mobility is reduced.

### DIAGNOSIS

Canine soft tissue injuries can be diagnosed in a couple of ways. We do not have the ability to ask the animal where it hurts or rather the animal does not have the ability to reply! Nor can we perform any resisted tests. This leaves us to utilize a strong background in anatomy and deductive reasoning. Thus our palpation skills and

Edge-Hughes, LM Anatomy, biomechanics, physiology, diagnosis and treatment of teres major strains in the canine. Proceedings of the RVC 2nd Annual Veterinary Physiotherapy Conference, Suppl. 2004.

the ability to ascertain how to stretch (stress) a sore muscle or tendon will be our strongest diagnostic tools for diagnosing soft tissue injuries.

The Teres Major muscle can be palpated from two different locations:

1. Just below the caudal angle of the scapula
2. Deep in the posterior axilla

In palpating you are looking both at observable muscle spasm or twitch as well as patient discomfort (as exhibited by a yelp, a whine, or an attempt to bite or flee.)

The Teres Major muscle can be stretched by fully extending the shoulder, allowing for full scapulothoracic movement (the front leg should be able to reach out forward in front of the body and up toward the dog's eye). It is easiest to cup the animal's elbow in the testers hand and use this point as a lever. To target the teres major specifically the tester can now apply an external rotation to the arm via the 'elbow-hold' as well as allowing a small amount of abduction. The tester is looking for spasm of the muscle, patient discomfort and also relative restriction of movement as compared to the non-affected side.

Accessory findings or theoretical correlations in conjunction to the finding of teres major strains include:

1. Cervical spine dysfunctions: primarily the segments of C6 – T1 (affecting the Axillary nerve which supplies the Teres Major muscle) or vertebral segments C7 – T2 (affecting the Thoracodorsal nerve which supplies the latissimus dorsi)
2. Rib Dysfunctions: Which may impede proper scapulothoracic rhythm or affect / tighten the latissimus dorsi.
3. Pelvis or lumbar dysfunctions: Which may also tighten the thoracodorsal fascia and hence latissimus dorsi (either mechanically if a backwards ilial rotation or neurally via nerve root facilitation in the low thoracic or lumbar spine).

#### DIFFERENTIAL DIAGNOSIS (other common shoulder lameness issues)

1. Biceps Tendonitis, Bursitis or Calcification
2. Supraspinatus Tendonitis
3. Infraspinatus Tendonitis or Contracture
4. Strain of Triceps (long head)
5. OCD of the shoulder
6. Osteoarthritis of the shoulder

#### TREATMENT OF TERES MAJOR STRAINS

Edge-Hughes, LM Anatomy, biomechanics, physiology, diagnosis and treatment of teres major strains in the canine. Proceedings of the RVC 2nd Annual Veterinary Physiotherapy Conference, Suppl. 2004.

Treatment of teres major strains must be based on acuteness or chronicity as well as the degree of injury. Naturally the sooner the injury is detected and treated, the sooner it will resolve and the animal can return to full activity level or competition.

Acute injuries which have occurred within the last 24 – 48 hours need rest and ice (in the axilla) applied for 10 – 20 minutes at a time. After this time, the injury site may benefit from a mild increase in blood flow to assist in reabsorption of traumatic exudates. This could be produced by low doses of ultrasound in the posterior axilla (I like 0.3 – 0.5 W/cm<sup>2</sup> at 25% pulsed for 5 – 8 minutes twice a week) and gentle stretching within a pain free range. Acupuncture also proves useful (via needles, laser, ultrasound or tens) targeting not only traditional points such as GV 14, GB34, LI 4 & LI 11 but also addressing ‘anatomical’ points such as SI 9 and H1. Low doses of laser and/or pulsed electromagnetic field (PEMF) can also be utilized.

Subacute injuries (from day 6 post injury to about day 21) require an influx of blood flow to bring in oxygen and nutrients as well as an infiltration of fibroblasts to help bridge the torn muscle or tendon fibres. These fibroblasts will be laying down their collagen fibres in random orientation. In order to trigger proper orientation or re-alignment of these collagen fibres the body needs low loads of normal stresses through the affected structure. This can be accomplished by active stretching (ie a play bow) or passive stretching of the teres major muscle as well as active contractions (ie. leash walking for concentric contractions and balancing exercises for isometric muscle contractions). Ultrasound doses can be increased (but I still like pulsed at this stage), as can laser or PEMF. Acupuncture can be continued also.

Late Stage injuries (day 21 and on) need re-orientation stimulus as well as overall muscle and tendon strengthening in a safe way so as to not re-injure the strain. If all is going well, the muscle should no longer be very tender on palpation and the animal should no longer be lame. Longer leash walks, incorporating hill walking (up hill would require concentric muscle contractions as the teres major and latissimus dorsi are trying to ‘pull’ the body up the hill and down hill would stretch the muscle as well as facilitate some eccentric muscle contractions) will be beneficial in this stage. Active dogs can be allowed to have very short bouts of off leash activity at the end of their leash walking (starting at 5 minutes per session and gradually increasing the time allowed off leash). Note: All dogs should have some on-leash ‘warm up time’ before being allowed off leash anyway!! Agility type activities can be built into the rehab regime. Low jumps in a straight line can begin to strengthen the muscle and, when all is well with this activity for few days, begin a series of low jumps and a recall turn towards the affected side. If this is non-problematic start a series of low jumps with a recall turn towards the unaffected side. Work at this for about a week before engaging in a full agility course. When setting up the course use long sweeping turns as opposed to those with tight turns and quick changes of direction. After this has been successfully implemented for a week the animal should likely be deemed fully recuperated and fit for full return to activity.

Chronic injuries can be a bit more problematic. They require lots of stretching to lengthen wound contractures and enhance collagen fibre orientation. The healed wound may be weak and irritated and hence it is helpful to actually stimulate a small amount of inflammation to restart the healing process. This can be done by utilizing higher doses of continuous ultrasound (shaving the hair will be necessary in this case to avoid overheating the hair and skin, as the protein in the hair will absorb the ultrasound waves and heat up according to researcher Jan Steiss, DVM, MScPT). Higher dosages of laser or pulsed electromagnetic field might also be helpful. See Edge-Hughes, LM Anatomy, biomechanics, physiology, diagnosis and treatment of teres major strains in the canine. Proceedings of the RVC 2nd Annual Veterinary Physiotherapy Conference, Suppl. 2004.

help for the same reasons. These animals can also be challenged by more advanced strengthening (hill walking for concentric and eccentric muscle strengthening). Although we are trying to strengthen the muscle, it should be stressed that the chronic injury patient must also be taken out of competition and disallowed from off-leash romps. Return to previous activity levels should be addressed as mentioned above.

## CONCLUSION

An understanding of anatomy is the key to the assessment, diagnosis and treatment of any musculoskeletal injury. A systematic ruling in or out of all soft tissue injuries will enable the practitioner to detect the site of injury and then target and treat it accordingly. Teres major strains should be suspected and assessed with any front leg lameness issue.

## References:

1. Magee, David J. Orthopedics. Conditions and Treatments. Fourth Edition Revised. Dept of Physical Therapy. Faculty of Rehabilitation Medicine. Copyright 1986.
2. Miller, Malcolm J.: Guide to the Dissection of the Dog. 1955, Edward Bros, Inc., Ann Arbor, Michigan.
3. Cyriax, James. Textbook of Orthopaedic Medicine, Volume One Diagnosis of Soft Tissue Lesions, Eighth Edition. 1982. W.B. Saunders, London, NW.
4. Sutton, Amanda. The Injured Horse, 2003, David and Charles Direct, Newton Abbot, TQ12 4ZZ

Edge-Hughes, LM Anatomy, biomechanics, physiology, diagnosis and treatment of teres major strains in the canine. Proceedings of the RVC 2nd Annual Veterinary Physiotherapy Conference, Suppl. 2004.